

Ref : 55825 Tudor^Archie

Sep 12, 2018

Diagnostic Imaging Report

Owner

Tudor

Referring veterinarian

Vets 4 Pets Cannock - Aleksandra Szczugiel

Patient

Archie : Dog West Highland White
Terrier

Male castrated 8 years

CT Performed on Sep 11, 2018

by James Weston

History

Hind limb paralysis.

Owner reports first episode of pain on the 31/08, but thought to be a stomach pain. On 08/08 started limping on LH.
At consultation today both hind legs with no proprioception, bilateral deep pain present.
Control of urination/defecation.

Description

The study consists of 6 series of 1 mm thick transverse CT images of the spine taken before and after intravenous injection of iodinated contrast medium.

On precontrast images, cervical, thoracic, lumbar and sacral vertebral bodies are well aligned delineating a vertebral canal of normal size. No aggressive or traumatic vertebral changes are identified. Mild ventral new bone formation is noted on the caudal aspect of the L1. A large amount of mineralised disc material is identified in the vertebral canal at the level of L1-L2 resulting in severe deformation of the spinal cord. A slight left-sided lateralisation is noted. A small amount of gas is seen in the L1-L2 intervertebral disc space, due to cavitation. Underlying thoracic and abdominal structures are within normal limits.

On post-contrast images, no abnormal enhancement is identified.

Conclusion

Ventral slightly left-sided extradural spinal cord compression due to massive L1-L2 disc extrusion.

Pr. Paul Barthez , DACVR, DipECVDI

Phone : +352 621 35 22 98

e-mail : paul.barthez@gmail.com

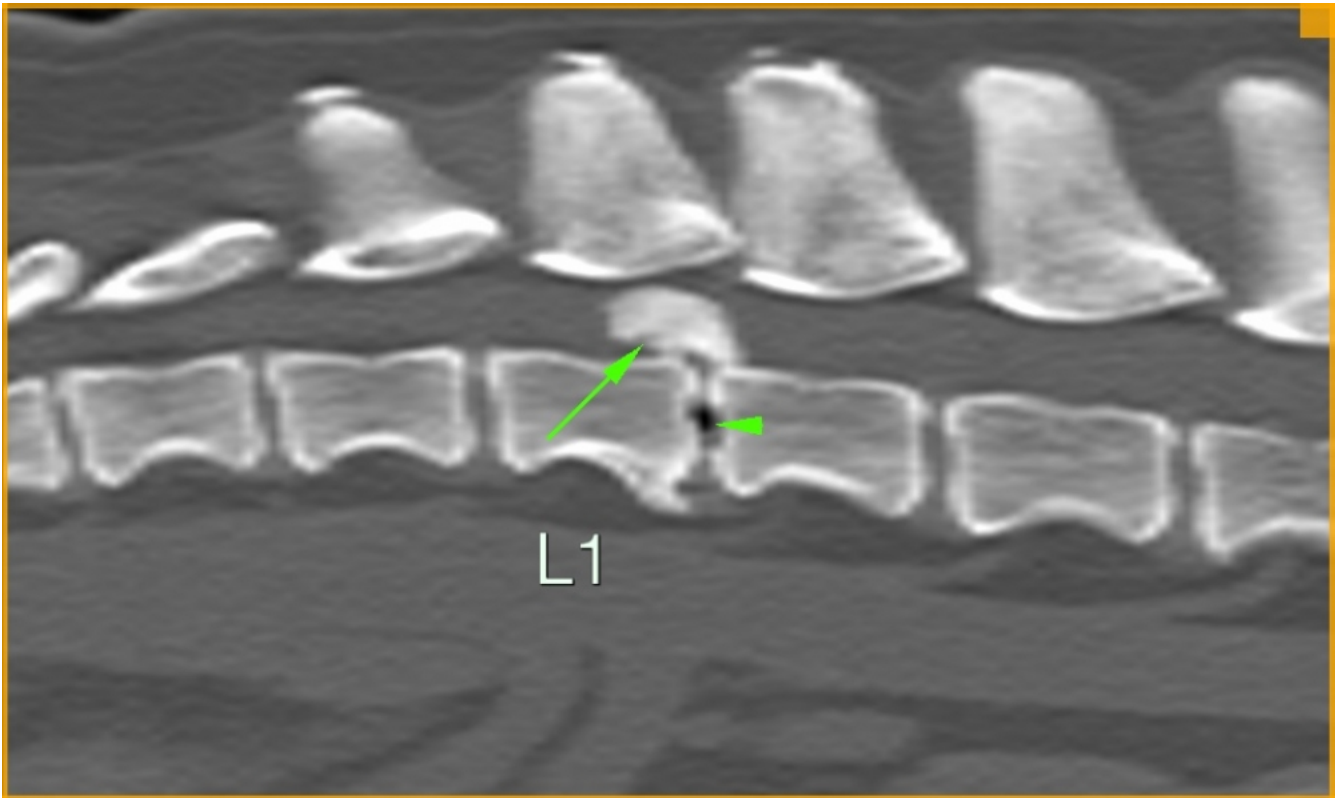


Fig.1 : Sagittal reconstruction of the thoraco-lumbar spine showing a large amount of mineralised disc material in the vertebral canal (arrow) at the level of L1-L2 and gas in the L1-L2 intervertebral disc space (arrowhead).

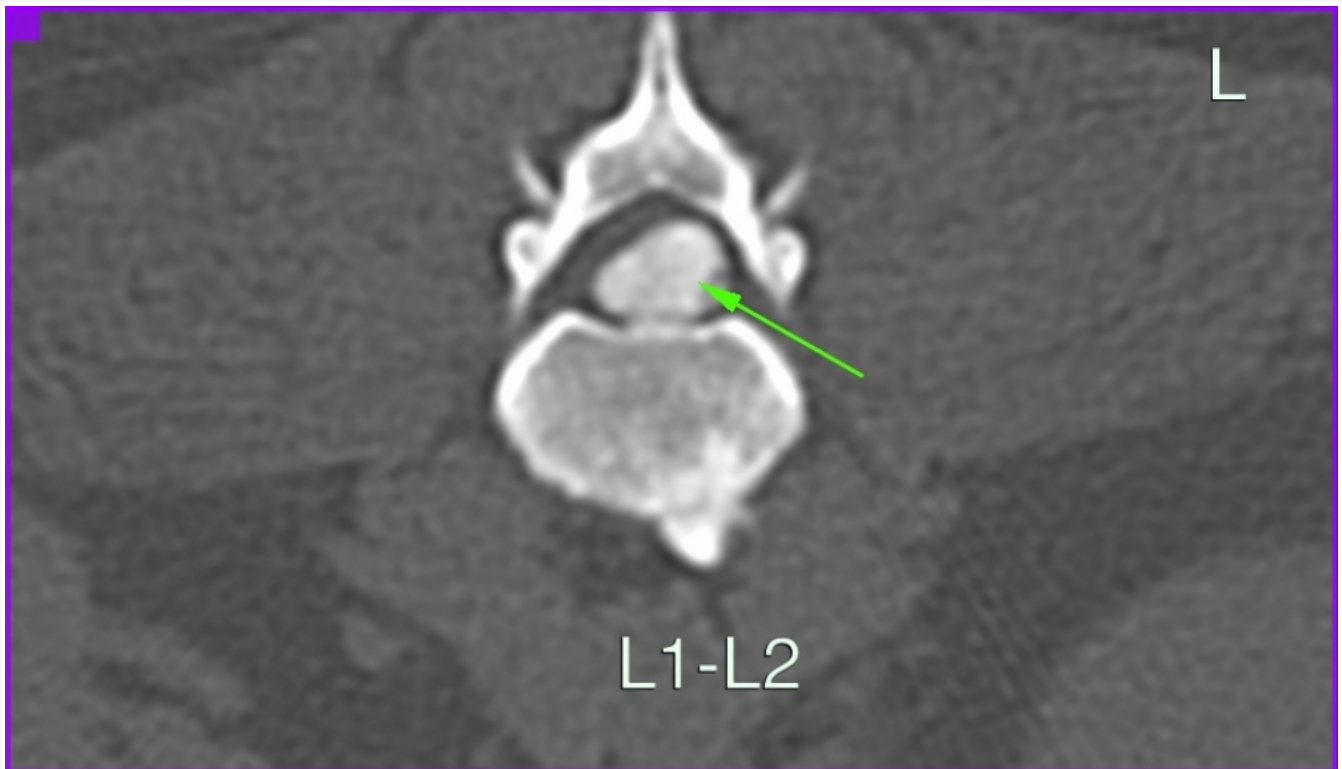


Fig.2 : Transverse image of the spine at the level of L1-L2 showing a large amount of mineralised disc material on the floor of the vertebral canal (arrow).